

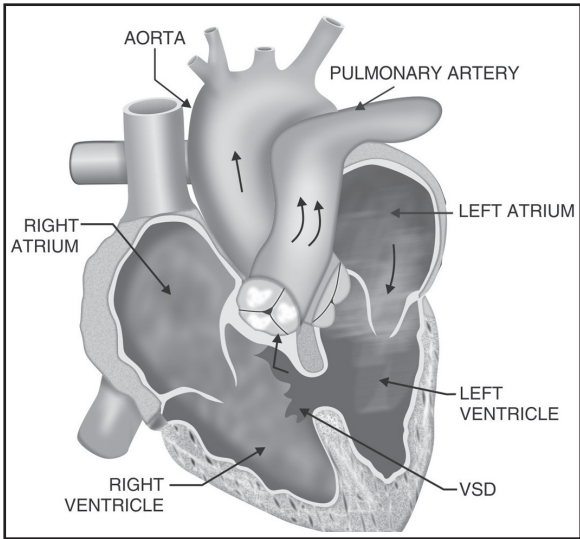Figure 6-4. Ventricular septal defect.

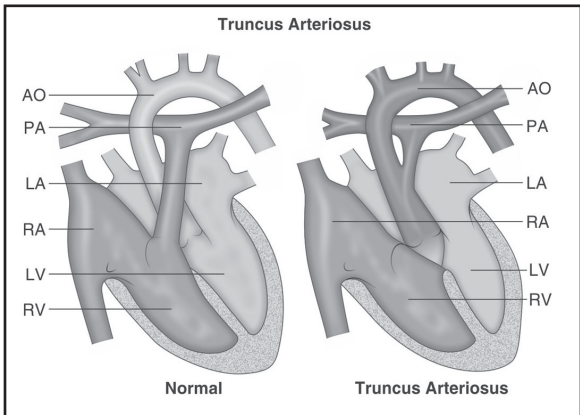


Figure 6-5. Truncus arteriosus.