

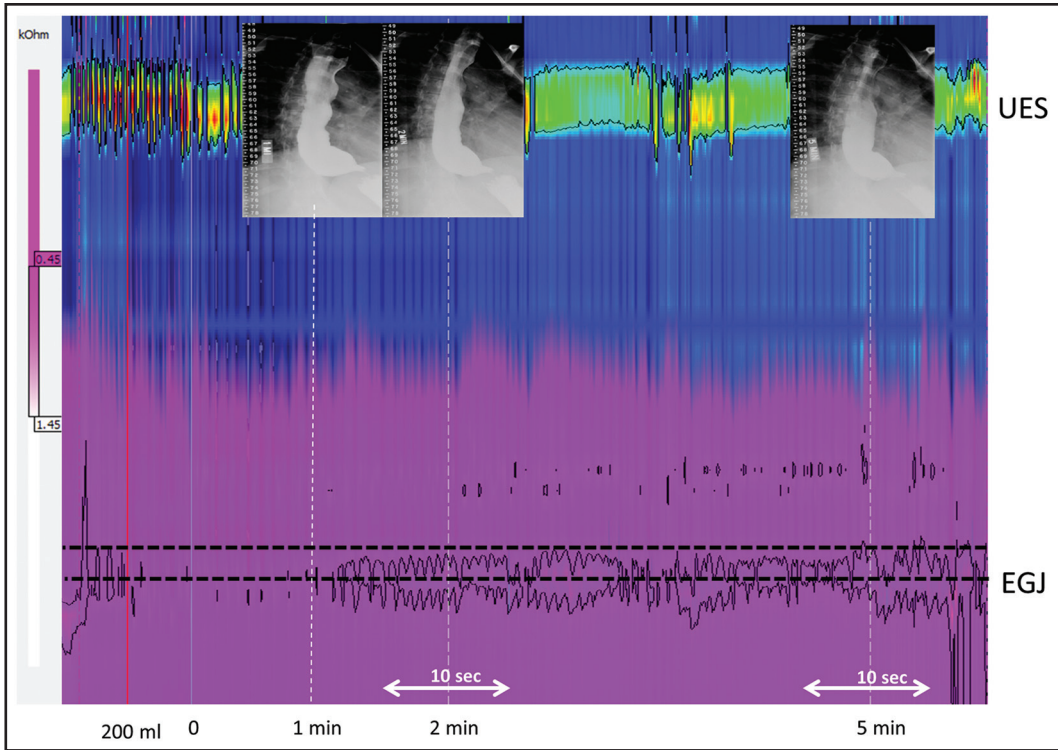Figure 3-3. High-resolution impedance manometry of achalasia with corresponding barium esophagram. Note the impedance color contour (purple) showing similar sustained bolus retention as visualized in a concomitant barium esophagram at 1, 2, and 5 minutes.

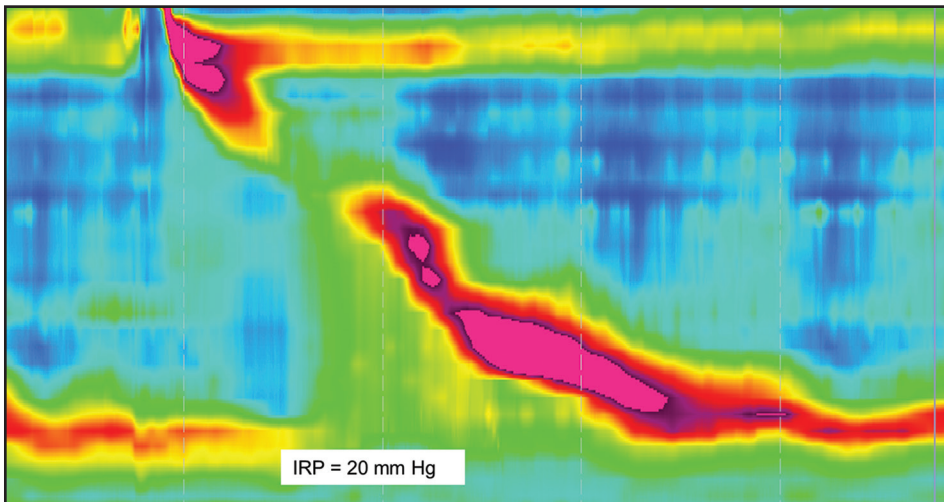


Figure 3-4. Examples of an EGJ outflow obstruction HRM pattern due to mechanical obstruction (prior fundoplication).

Italy of 1.59 cases/100,000/year (2001 to 2005). Research using the U.S.-based Clinical Outcomes Research Initiative (CORI) database of endoscopic procedures found that among 521,497 upper endoscopies performed from 2000 to 2008, 896 patients with achalasia were identified (0.2%).¹⁸ There may be an increased risk with advanced age, but overall, achalasia affects both men and women of all races and ages fairly equally. More recent studies have suggested a higher incidence