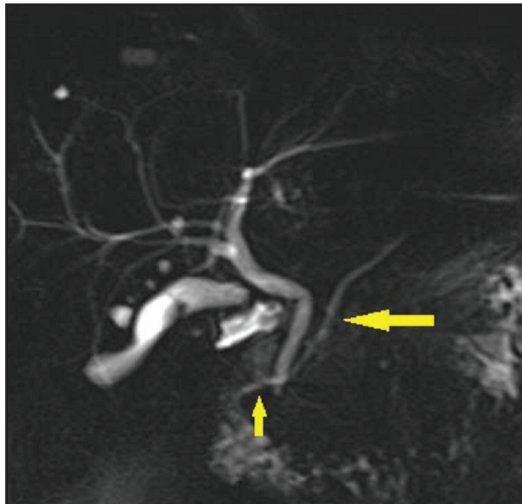


## Vignette 24: Divided We Fall

You are excited to see a 31-year-old woman in the clinic for chief complaint of chronic abdominal pain. For over a decade, she reports generalized, persistent discomfort that worsens with meals and improves after a bowel movement. She also reports constipation alternating with diarrhea. She has had a 5-lb weight gain over the last 12 months. Vital signs are temperature 98.3°F, blood pressure 118/75 mm Hg, pulse 75 beats/minute, and oxygen saturation 99% on room air. On physical examination, the patient is well appearing and in no acute distress. She has mild diffuse abdominal tenderness to palpation without rebound or guarding. She has brought records from prior evaluations, which include a normal complete blood count, normal serum chemistry, normal amylase and lipase, normal liver tests, and normal thyroid tests. As part of the evaluation, MRCP was obtained (Figure 24-1).



**Figure 24-1.** MRCP image.

- ▶ *What anomaly is present on the patient's MRI?*
- ▶ *Is an ERCP warranted?*