

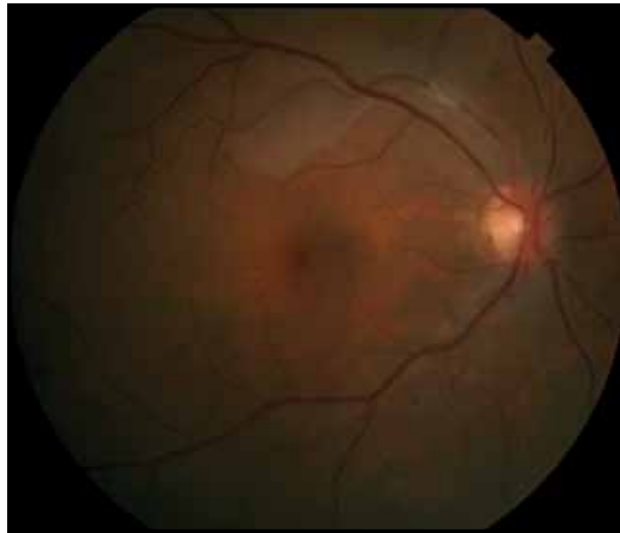
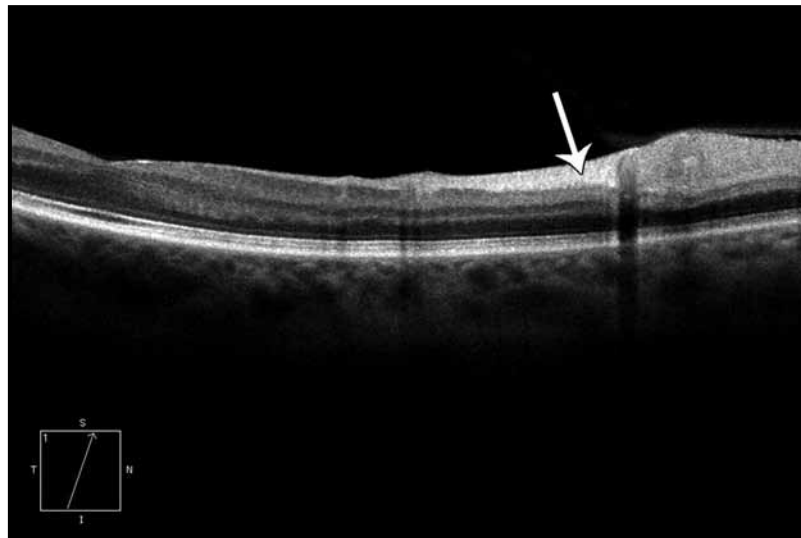
Case 4-1A. Acute Branch Retinal Artery Occlusion

Clinical Summary

A 56-year-old female complains of blurry vision in the inferior visual field of the right eye for 3 hours. She had undergone an aortic valve replacement 3 months prior to presentation. Visual acuity measures 20/60 in the right eye, with loss of inferior field. Dilated fundus examination reveals an intra-arterial embolus along the superotemporal arcade with smaller embolus distally, with associated retinal whitening (A).

Optical Coherence Tomography

Horizontal OCT scan (B) through the corresponding area (C) shows intraretinal thickening with hyperreflectivity of inner retinal layers (arrows). Additionally, focal areas of shadowing correspond to retinal arteries and veins. The superior macula is thickened to 302 μm (D). The patient's Humphrey visual field defect correlates to the area of ischemic retina (E).

**A****B**