

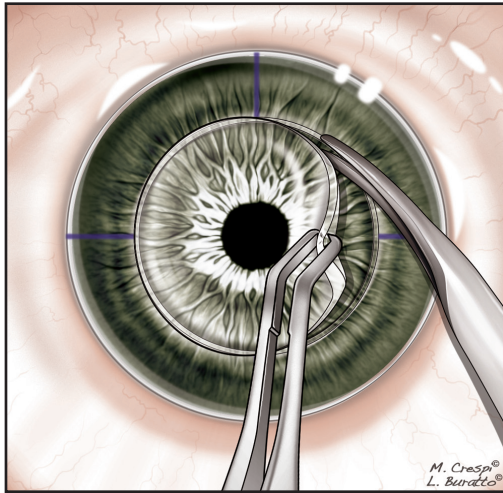Figure 17-7. Removal of the host bed.

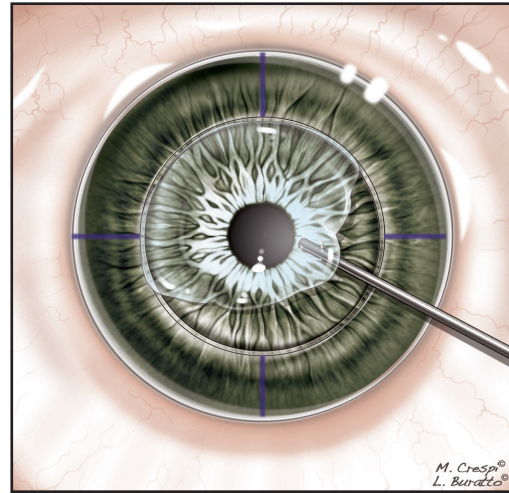


Figure 17-8. Open-sky placement of dispersive VES.

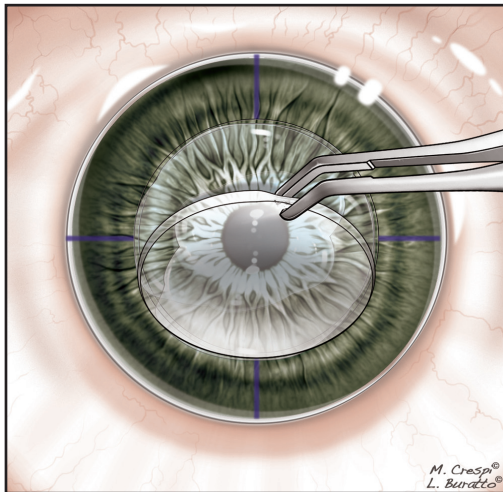


Figure 17-9. Placement of the donor flap following washing. The pupil is in pharmacological miosis and the IOL is in the capsular bag.

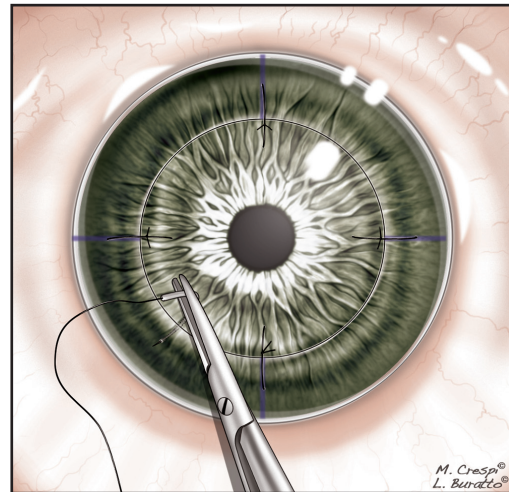


Figure 17-10. Placing 4 individual sutures of 10-0 nylon.

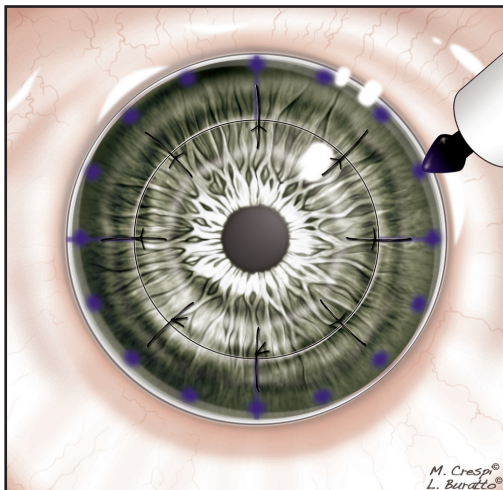


Figure 17-11. Sixteen points are marked.

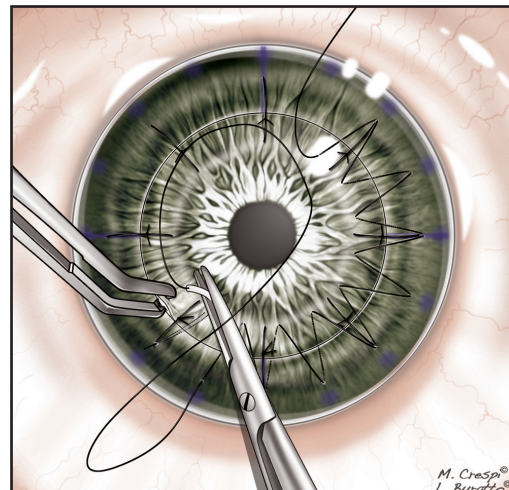


Figure 17-12. Continuous running suture with 16 passes.