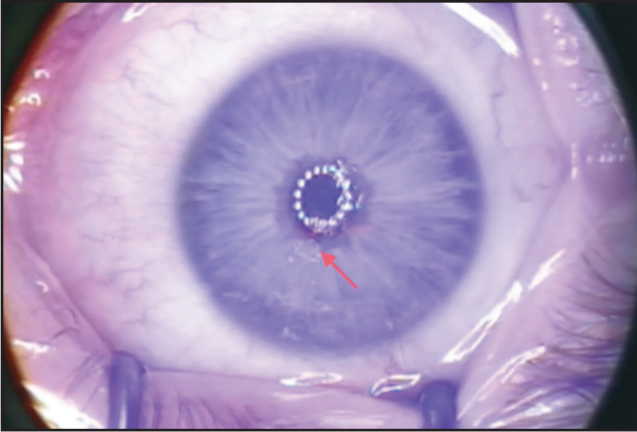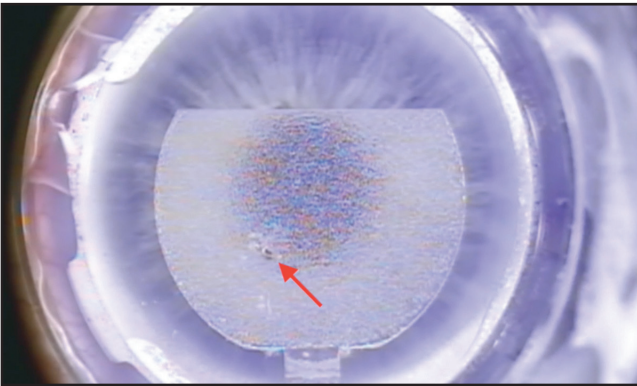


**Figure 10-8.** Initial surgery showed an epithelial defect (red arrow).



**Figure 10-9.** Uncut area at the epithelial defect zone (red arrow).

## *Complication #4: Iatrogenic Epithelial Defect During Docking (Flap Unable to Lift)*

**Video section: 8 minutes 39 seconds**

Platform: WaveLight FS200

Flap diameter: 9.3 mm

Flap target depth: 100  $\mu$ m

The initial surgery resulted in an incomplete flap due to an iatrogenic epithelial defect. Adherence was found during dissection at the place of the epithelial defect (video 10; time: 8 minutes 39 seconds; Figures 10-8, 10-9, and 10-10).