

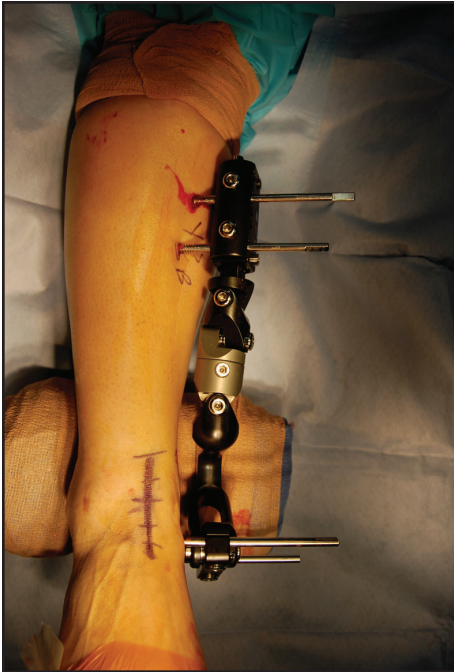

Figure 8-6. A unipolar external fixator placed across the ankle joint provides temporary distraction that facilitates surgical exposure.

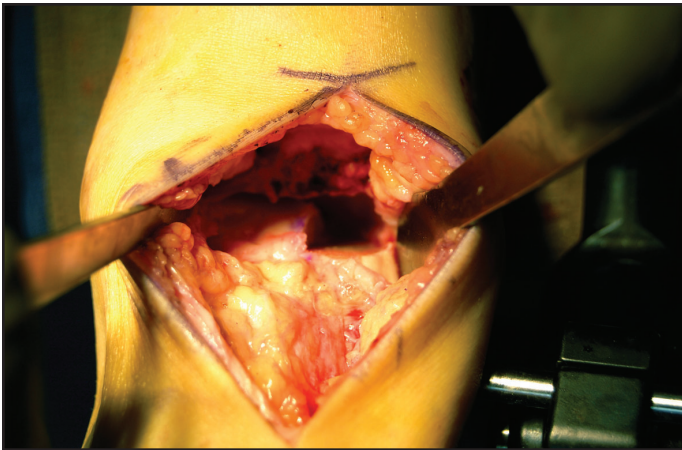


Figure 8-7. Preparation of the recipient site after completion of both the vertical and horizontal cuts.

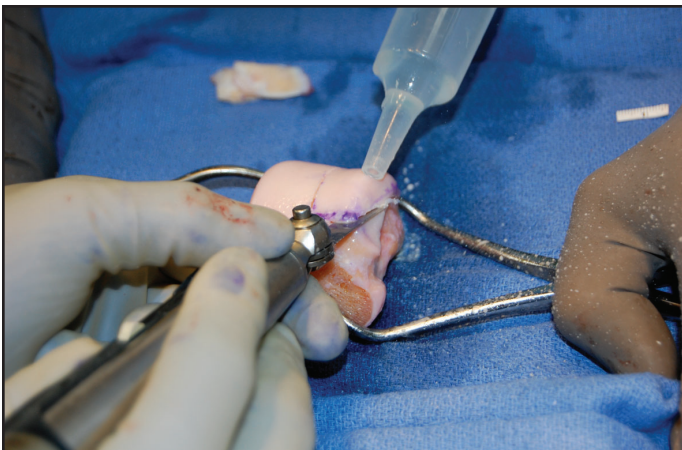

Figure 8-8. The allograft is removed from the donor talus following similarly performed resection along the measured and marked dimensions of the recipient site.