

Figure 31-3. (A) Lateral view demonstrating the one screw used to hold the posterior malleolus fragment. The screw was placed through a small stab incision on the anterior border of the tibia. (B) Lateral view of a patient presenting with a large posterior fragment. A plate was used to stabilize the posterior fragment placed through a separate posterior incision.

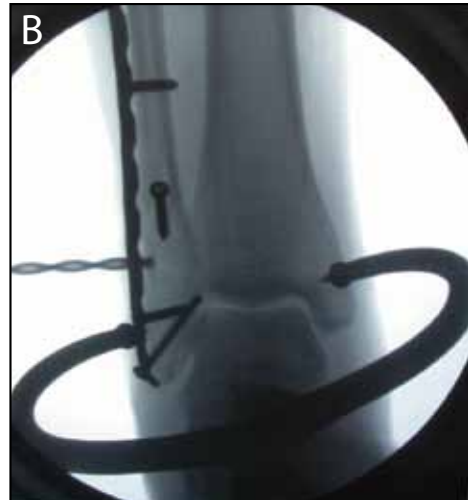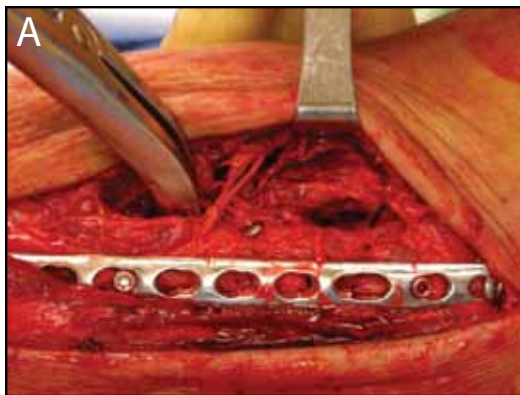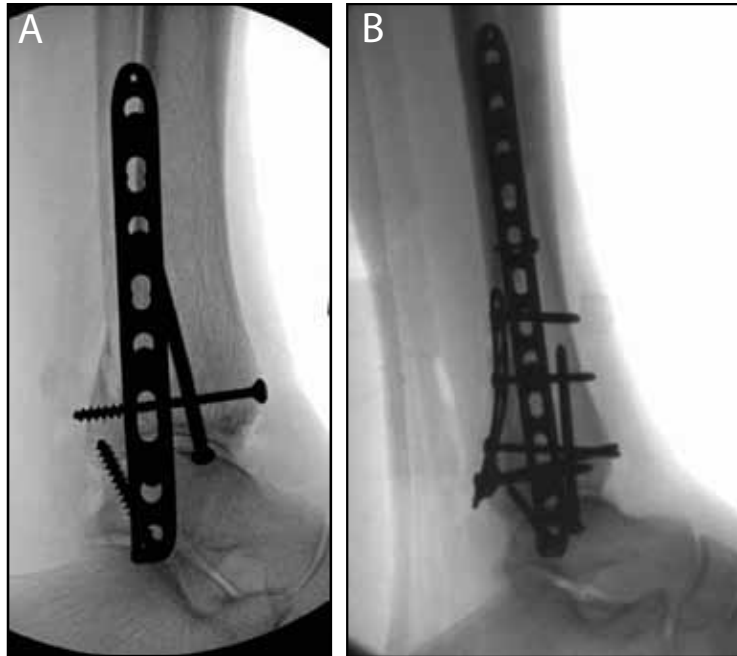


Figure 31-4. (A) Dissection anterior to the fibula onto the tibia with application of a lamina spreader to allow visualization of the syndesmosis. (B) After débridement of the syndesmosis, the fibula is reduced into the incisura and held with a bone clamp prior to fixation.

placed across three or four cortices of bone. Screws should be placed 2 to 5 cm proximal to the plafond. Newer implants, including absorbable and suture devices, are also available for fixation of the syndesmosis. The advantage is that these implants do not require removal, but there is some concern that failure of fixation and subsequent widening of the syndesmosis may occur with these devices. Regardless of the implant chosen for fixation of the syndesmosis, the authors' preferred postoperative treatment