

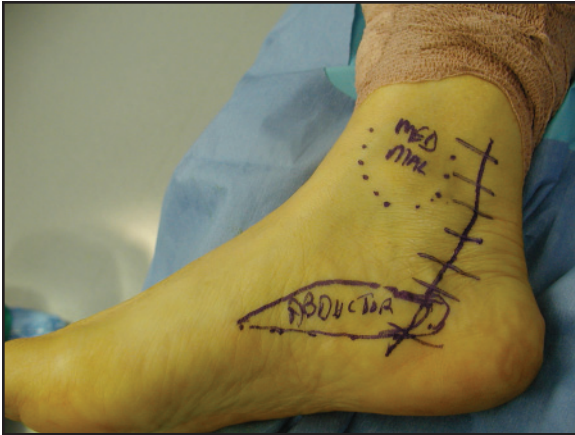Figure 9-1. Incision for distal tarsal tunnel release.

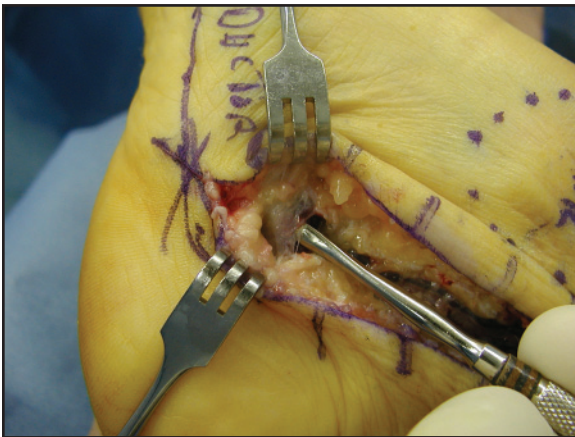


Figure 9-2. The flexor retinaculum is released and the superficial fascia of the abductor is being shown.

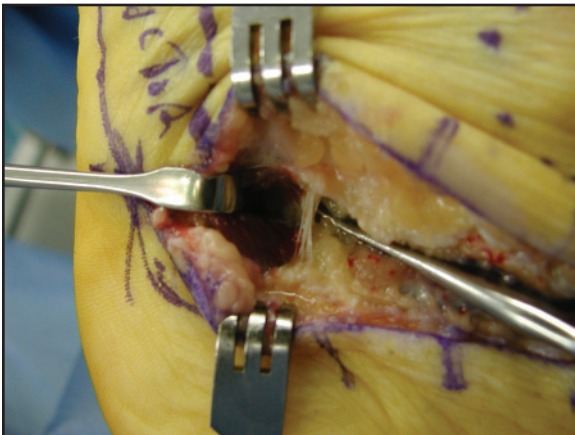

Figure 9-3. The superficial and fascia of the abductor hallucis is released and the deep fascia is shown. The lateral plantar nerve lies directly beneath this layer.