

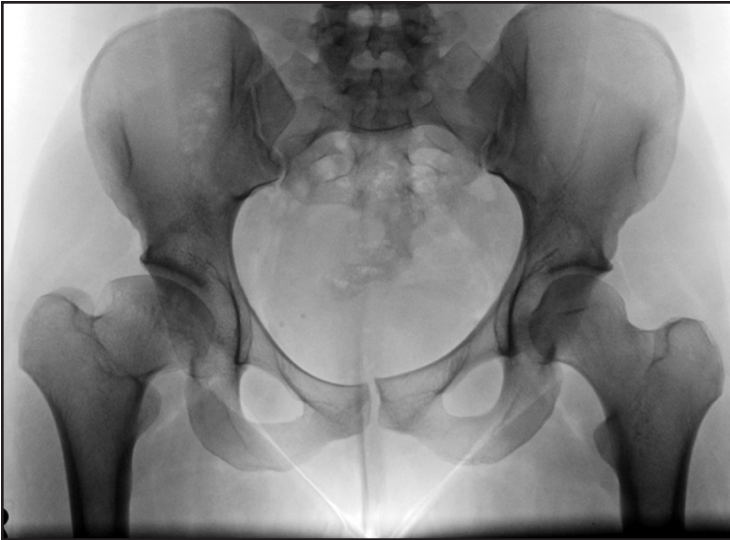

Figure 11-4. Preoperative radiograph of a 22-year-old woman with a dysplastic right hip and Perthes-like deformity of her right hip.

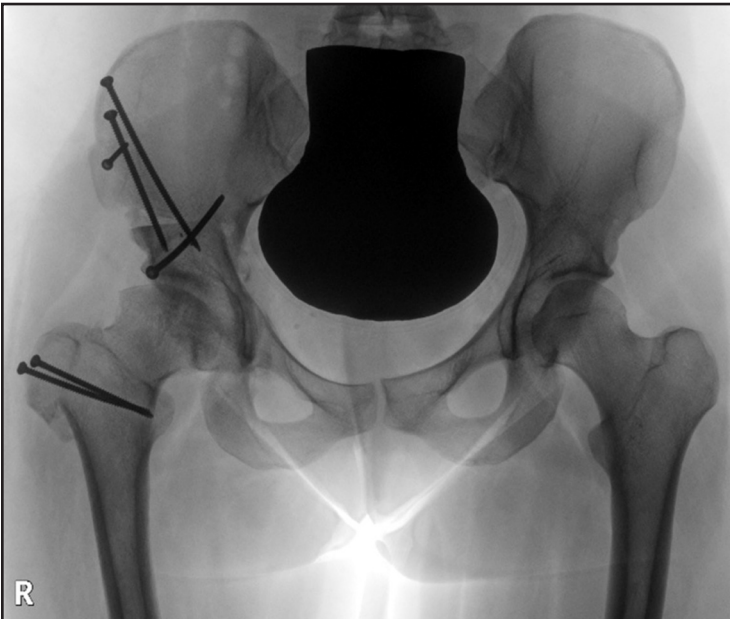


Figure 11-5. Same patient after right PAO and surgical dislocation of the hip with osteochondroplasty of the head-neck junction and advancement of the greater trochanter.