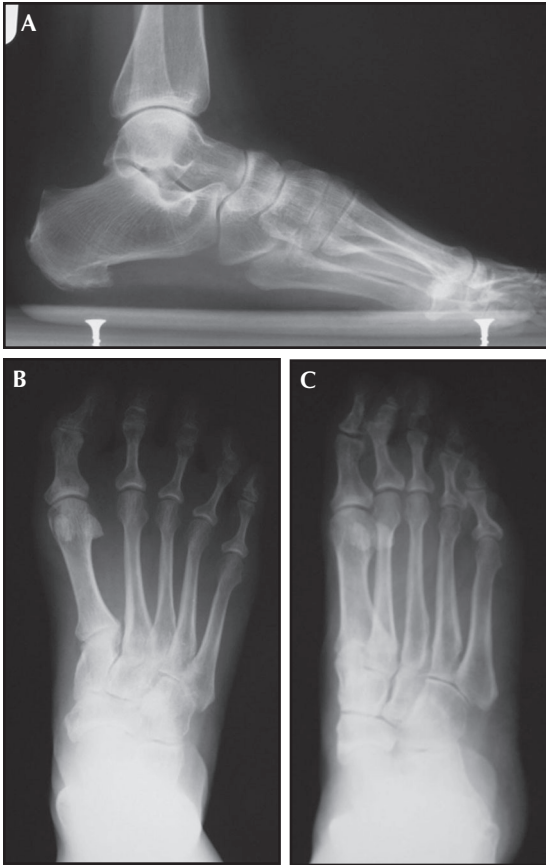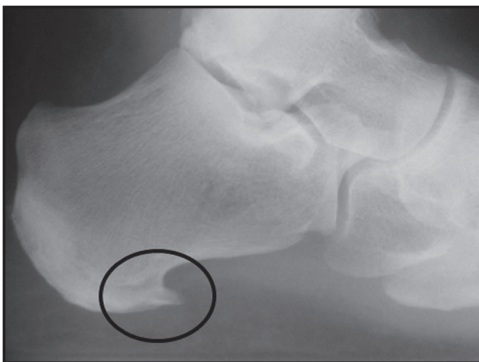




**Figure 11-5.** Standard weight-bearing radiographs of the foot should include (A) lateral, (B) AP and (C) oblique views. Routine evaluation should include overall alignment, assessment of degenerative arthritis, calcific tendinopathy and the exclusion of additional sources of pain.



**Figure 11-6.** Calcaneal traction spur. Standard weight-bearing lateral radiographs of the foot often show evidence of underlying pathology. The presence of calcification along the insertion of the plantar fascia represents a secondary response to chronic traction stress on the periosteum of the calcaneus.