

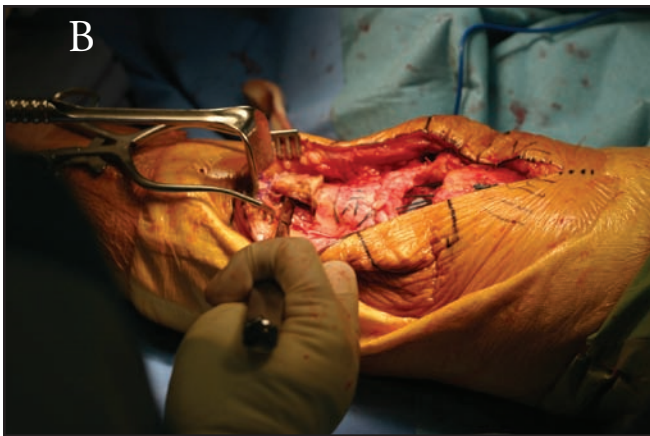
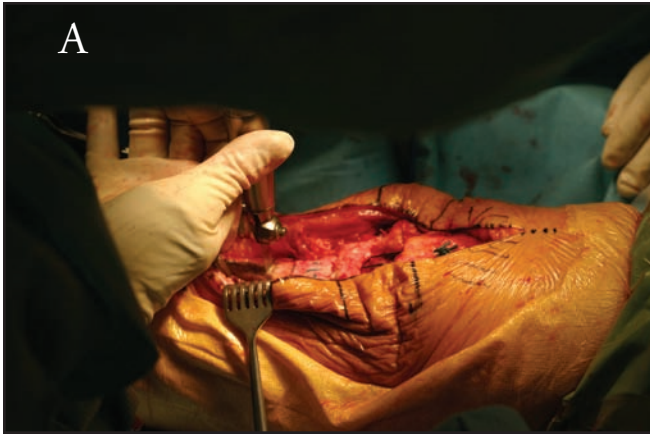
Figure 17-6. (A) The proximal part of the tibia is prepared for insertion of the calcaneal bone block. A small saw is used to make a rectangular/trapezoidal cavity. (B) Osteotome is used to lift out the unwanted bone.

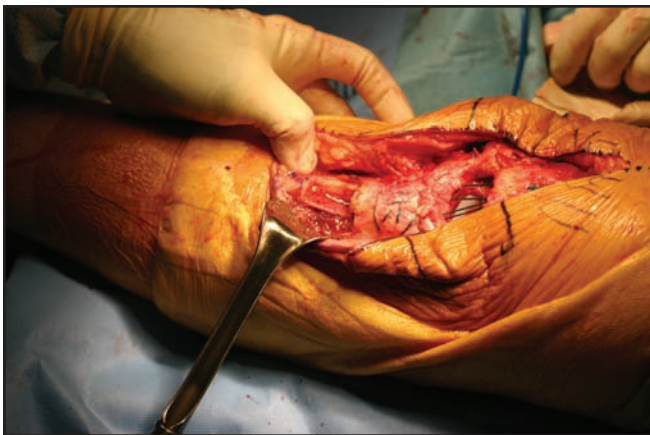


Figure 17-7. Prepared proximal tibia cancellous bed.

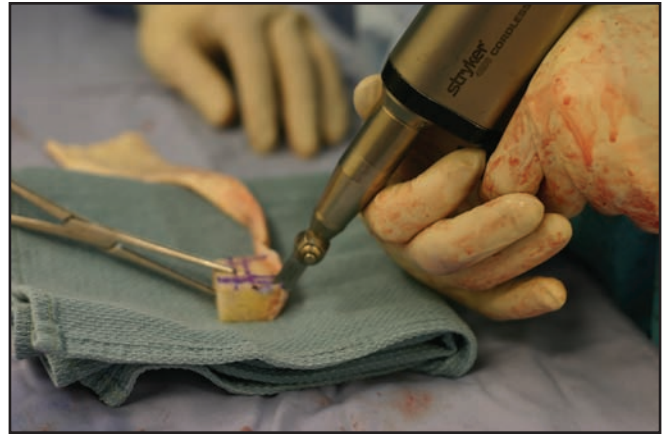

Figure 17-8. The calcaneal bone block is cut to match the created rectangular/trapezoidal space in the proximal tibia.

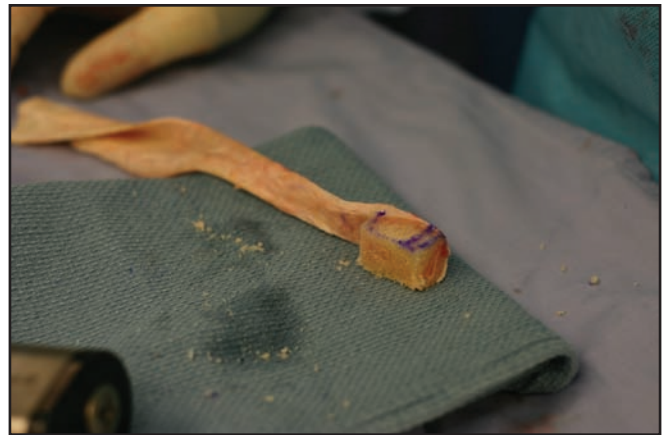

Figure 17-9. A "key stone" is created to maximize friction fit and bony contact.

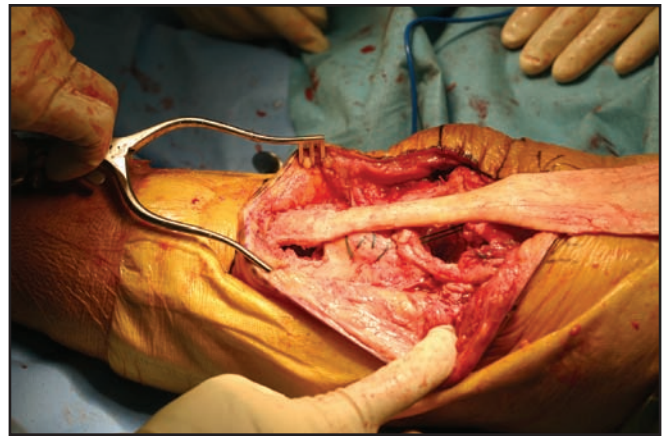


Figure 17-10. The bone block is gently impacted into the proximal tibial.