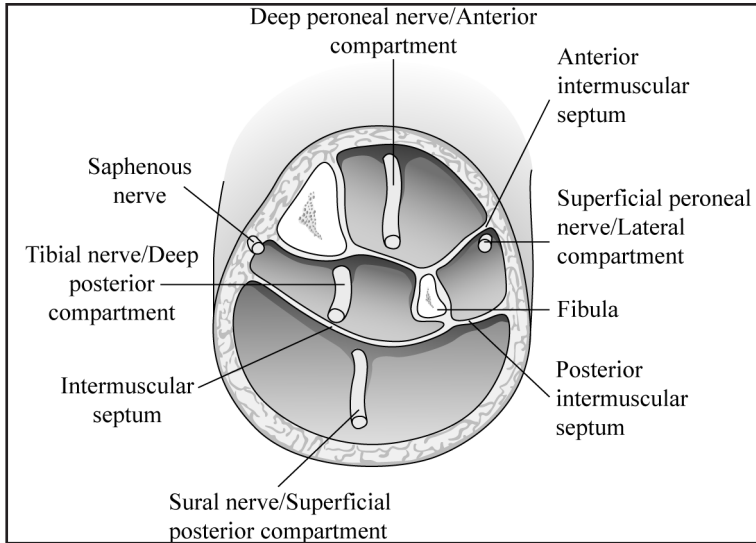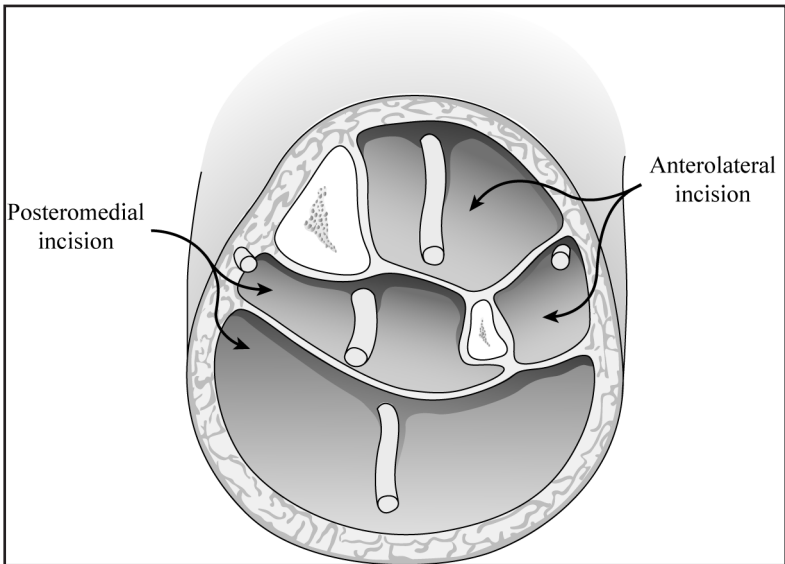


**Figure 28-1.** Compartments of the lower leg and their associated structures.



**Figure 28-2.** Diagram depicting a 2-incision fasciotomy of the lower leg.